On the list of weapons, laser pointers?

Canetas a laser na lista de armas?

Rakesh Kumar Jha[1], Bhupesh Bhatkoti[2], Jaya Kaushik[3]

[1] Department of Ophthalmology, Military Hospital Wellington, India.
[2] Department of Ophthalmology, Command Hospital, Pune, India.
[3] Department of Ophthalmology, Command Hospital, Lucknow, India.

How to cite:
Jha RK, Bhatkoti B, Kaushik J. On the list of weapons, laser pointers? Rev Bras Oftalmol. 2026;85:e0004.

doi:
https://doi.org/10.37039/1982.8551.20260004

Keywords:
Macular degeneration; Weapons; Lasers

Descritores:
Degeneração macular; Armas; Lasers

Received on:
October 18, 2025

Accepted on:
November 7, 2025

Corresponding author:
Rakesh Kumar Jha
Department of Ophthalmology, MH Wellington, Coonoor Road.
643231 – Nilgiris, Tamilnadu, India
E-mail: rkjhan2@y7mail.com

Institution:
Department of Ophthalmology, MH Wellington, Coonoor Road.

Conflict of interest:
no conflict of interest.

Financial support:
no financial support for this work.

Associate Editor:
Ricardo Augusto Paletta Guedes
Universidade Federal de Juiz de Fora, Juiz de Fora, MG, Brazil
https://orcid.org/0000-0002-9451-738X

Copyright ©2025

A 35-year-old man presented to the ophthalmology clinic with immediate blurry vision and central scotoma in the right eye after sustaining accidental exposure to a handheld laser pointer (power < 1 mW, wavelength 640 to 660 nm; according to the label on the device) from approximately 5 m away, for a duration that he described as 1 to 2 seconds during a PowerPoint presentation in a conference room. Visual acuity was 20/80 in the right eye and 20/20 in the left eye. Color fundus photograph showed loss of foveal reflex with well-circumscribed elevated yellow-orange spot at the foveola (Figure 1A, black arrow) encircled by faint grey coloration in the right eye. Optical coherence tomography (OCT) of the right macula revealed a focal hyperreflectivity at the fovea in a vertical orientation with disruption of the retinal pigment epithelium (hyporeflective cavitations inside the retinal pigment epithelium and photoreceptor segments at the fovea (Figure 1B, white arrow).

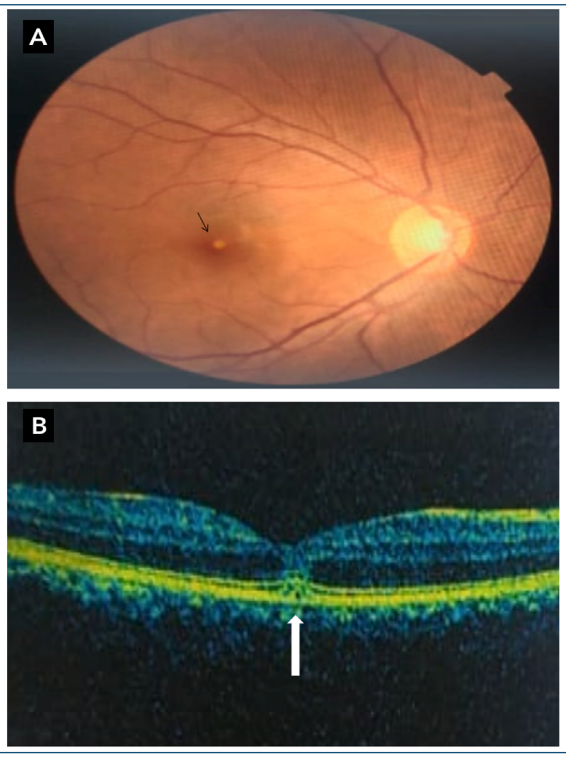

Figure 1. Laser-induced maculopathy. (A) Color fundus photograph of the right macula depicting a well-demarcated yellow spot at the fovea. (B) Optical coherence tomography image of the right macula demonstrating hyperreflectivity at the fovea, with focal disruption of retinal pigment epithelium interdigitation zone (focal hyporeflective cavitations within the RPE) and in the inner and outer photoreceptor segments at the fovea.

The right eye was diagnosed with a laser pointer induced photic maculopathy. Photic maculopathy is a type of retinal photochemical injury caused by ultraviolet radiation due to solar eclipse viewing, direct sun gazing, arc welder gazing or laser pointer exposure, as in this case. Handheld lasers are generally safe for human eyes if the users have general awareness of its potential hazards and knowledge of safe handling. The Food and Drug Administration (FDA), as such, regulates the sale of handheld laser limited to Class II or IIIa lasers with outputs of a maximum of 5 mW and wavelengths between 635 and 750 nm.[1] However, handheld lasers ranging from 5 mW to 500 mW (class IIIa) or greater than 500 mW (class IV) are readily available online or at street markets, with some even being sold with incorrect labeling to lower class compared to their actual high-power output. Direct ocular exposure to such handheld device with lasers of power more than 5 mW and shorter wavelength (green and blue laser; wavelength 490 to 575 nm) may lead to retinal damage. Although visual recovery can occur over a period of months, central scotoma or metamorphopsia may be permanent in some cases.[2]

He was treated with a topical nonsteroidal antiinflammatory drug daily for 12 weeks. His vision gradually improved to 20/20 in the right eye by 12 weeks, and had no residual scotoma.

AUTHORS' CONTRIBUTION

Rakesh Kumar Jha contributed to the conception and design of the study, analysis and interpretation of results and writing of the first Draft. Bhupesh Bhatkoti and Jaya Kaushik contributed equally to the analysis, critical review of the manuscript's content and writing of the final draft. All authors approved the final version of the manuscript and are responsible for all aspects of the manuscript, including ensuring its accuracy and integrity.

REFERENCE

1. Occupational Safety and Health Administration. OSHA Technical Manual (OTM) Section III: Chapter 6. Published 2021 [cited 2025 Nov 6]. Avalaible from: https://www.osha.gov/otm/section-3-health-hazards/chapter-6
2. Martín-Moro JG, Verdejo JH, Gallardo JZ. Photic maculopathy: A review of the literature (II). Arch Soc Esp Oftalmol (English Edition). 2018;93(11):542-50.